

Research Journal of Pharmaceutical, Biological and Chemical Sciences

Evaluation of Implications Potentials of Dietary Supplement (Yeast Tablets) On Pregnant Albino Rats and Their Offspring's.

Amel R Omar*, Eman Y Salah EL-Din, and Heba A Abdelrahman.

Department of Zoology, Faculty of Science, Cairo University, Egypt.

ABSTRACT

The aim of this study to assess the effect of yeast tablets on the pregnant rats and their litters. The pregnant rats were administered orally with yeast tablets at a dose of 41.1 mg/kg rat from day 5 up to 19 of pregnancy and the mothers were sacrificed on day 20 of pregnancy. The maternal external toxicity symptoms and external anomalies of fetuses were reported and skeletal abnormalities were investigated. Oral administration of yeast to pregnant rats resulted in statistical differences regarding to the dams weight, fetal weight and length were significant. There are number of postimplantation resorptions and external malformations of fetuses were recorded. Some fetal skeletal abnormalities were observed.

Keywords: *Rattus norvegicus*- *Saccharomyces cerevisiae*- Skeletal abnormalities- Yeast tablets

*Corresponding author

INTRODUCTION

Saccharomyces cerevisiae is a species of yeast that has been used for centuries for a variety of processes such as brewing and bread-making. More recently, yeast and yeast cell wall components have been used as a supplement in the nourishment of beef and dairy cattle [1], swine [2], lambs [3] and poultry [4]. Live yeast products and their derivatives (i.e., yeast cell wall products) are now utilized in food animal production for a diversity of reasons encompassing performance enhancement and generally benefits to animal health and well-being [5]. Yeast tablets rich with vitamins B-complex, proteins with essential amino acids, minerals and elements; selenium, chromium which are important for human body.

Yeast-based products have ability to enhance immunity and health during stressful events by acting as immunomodulators and biological response modifiers, so justifying some of the negative effects associated with pathogenesis and morbidity [6]. Also, probiotics have the ability to stimulate the intestinal immune system and to increase the production of antimicrobial peptides and cytokines in the intestinal tract; modulation to the intestinal immune functions [7&8]. The supplementation of diets fed to sows with a probiotic preparation; *Saccharomyces cerevisiae boulardii* were recorded non-significant reproductive problems such as abscess, Mummies, Mortality, Stillborn, Weak, and abortion [9].

In light of most recent studies, [10] conclude that Cr (III) can directly cause genetic mutations in yeast and Jurkat cells. In contrast, Cr (III) was initially considered a relatively nontoxic agent that plays an important role in regulating blood glucose levels and is regarded as a dietary supplement [11&12]. Studies in cell-free systems demonstrated that Cr (III) does bind to DNA, leading to a decrease in the fidelity and an increase in the processivity of DNA polymerases, which may ultimately lead to increased mutations [13]. While, the potential for genotoxic side-effects of Cr (III) complexes may outweigh their possible benefits as insulin enhancers and that recommendations for their use as either nutritional supplements or antidiabetic drugs need to be reconsidered [14]. Also, Data in vitro studies show that Cr (III) has the possibility to react with DNA and responsible for DNA damage in cell culture systems, but under normal conditions, restricted access of Cr (III) to cells in vivo minimize or prevents genotoxic effect in the biological systems. The available in vivo evidence suggests that genotoxic effects are very unlikely to occur in humans or animals exposed to nutritional or to moderate recommended supplemental levels of trivalent chromium [15].

In spite of the safety and good effect of the dietary supplement (yeast tablets) which investigated in the previous literatures. In Pregnancy, there is not enough reliable information about the safety of taking brewer's yeast by mouth if you are pregnant. Stay on the safe side and avoid use. So we encouraged to do this research to investigate the safety of it.

MATERIALS AND METHODS

Drug

The yeast used in the current study contains each tablet on 66.66mg of dry yeast extract which tantamount to 500 mg of medical yeast. It produced from Arab Company for medicines and medicinal plants. MEPACO-Midi delegations (Anshas-East) Egypt.

Animals

Healthy male and nulliparous female albino rats *Rattus norvegicus* (170-180g) were obtained from the animal house of the Faculty of Veterinary Medicine, Giza, Egypt. Animals were housed in polycarbonate boxes with steel-wire tops (not more than five animals per cage) and bedded with wood shavings. Ambient temperature was controlled at 22 ± 1 °C with a relative humidity of $55 \pm 5\%$ and a 12-h light/dark photoperiod [16]. Food and water were provided ad libitum. The study was carried out after acceptance from The Institutional Animal Care and Use Committee (IACUC) with approval number (CUFS/F/28/15). Breeding was established by housing two females and one male. The females were examined daily to see the pregnancy chance. Those animals showing vaginal plug were isolated and the day of pregnancy was registered.

Experimental studies

Pregnant females were specified into control and test groups containing twelve animals for each. The treated group administered orally with yeast tablets at a dose of 41.1 mg/kg rat from day 5 up to 19 of pregnancy. The control animals receive equal amount of distilled water. The dosing judgment was based on human equivalent/therapeutic dose (HED).

At the 20th of gestation each dam was submitted to cesarean section. The animals were anesthetized with Sodium pentobarbital. The abdomen was incised; the gravid uterus was removed and weighed with its contents, total implantation sites, fetal mortality rate (resorbed or still birth), living fetuses were recorded and post-implantation loss index calculated according to (Christian, 2001).

post-implantation loss index = $\frac{\text{No. of implantation sites} - \text{No. of live fetuses}}{\text{No. of implantation sites}} \times 100$

The toxicity of treated dams was determined by observations of external symptoms, maternal mortality and change in body weight. The weights of the pregnant rats recorded at the 1st and 20th days of gestation and calculate the percent of change in maternal weight through the gestation = $\frac{\text{wt. of 20}^{\text{th}} \text{ day} - \text{wt. of 1}^{\text{st}} \text{ day}}{\text{wt. of 20}^{\text{th}} \text{ day}} \times 100$.

Fetal preparation

The fetuses were examined for external malformations; their body weight and length were recorded. After that, the fetuses were prepared for skeletal preparation by placed them in 95% ethanol for dehydration, where they remained for 10 days. After completion of dehydration, their skins and viscera were removed and the fetuses were transferred into pure acetone for 24 hours to remove the fats.

Alcian blue and Alizarin red staining

Staining was carried out for 7 days at 40° C. The staining solution was prepared as follows:

- 1) 300 mg Alcian blue dissolved in 100 ml 70% ethanol: 1 volume (100 ml)
- 2) 100 mg Alizarin red dissolved in 100 ml 95% ethanol: 1 volume (100 ml)
- 3) Glacial acetic acid: 1 volume (100 ml)
- 4) 70% ethanol: 17 volume (1700 ml)

The above components mixed together in the order 1 and 2 then 3 and then 4 to get the staining solution. 100 ml of the solution were be used per total eviscerated rat fetus, thereafter the sample were washed with tap water for 2 hours. The fetuses were placed the specimens in 2% aqueous KOH for 2 days. 20% containing 1% KOH was added to the fetuses unto the skeleton be clearly visible. Finally, the specimens were cleared by placed them in successive Glycerin solution with concentrations 50%, 80% and 100% respectively for 7 days to each [17].

Statistical analysis

All statistical analyses were performed using PASW statistical version 18. Statistical analysis was performed using one-way analysis of variance (ANOVA) to assess significant differences among the treated and control groups. Data are expressed as mean (μ) \pm standard error (SE) and $P < 0.05$ was considered statistically significant.

RESULTS

Morphological studies

Yeast effect on pregnant rats

Yeast tablets used in this study is orally treated to the pregnant albino rats from fifth to twentieth day of gestation exhibit some abnormalities to mothers. The mean of treated maternal body weight change was

significantly increased compared to control group (Table 1). Concerning on the uterus, the treated mothers showed complete resorption of the all implanted embryos (Figs. 1C&1D) or a resorbed site on the right horn (Fig. 1B) compared to the control one that revealed equal distribution of fetuses (Fig. 1A). During the surgical operation we find an abscess in the pelvic region of a mother (Fig. 2) and a number of fat cells on the mother's kidney (Figs. 3)

Table 1: Showing effect of yeast tablets on mother weight gain, fetus weight and fetus length at 20th day of gestation. a= P ≤ 0.05 compared with control.

Group	Change in Mother weight (%) (M.WT%)	Fetus weight (F.WT)	Fetus length (F.L)
Control	13.82±1.44	5.66±0.13	3.82± 0.07
Treated with 41.1 mg/kg	25.83±2.89 ^a	3.93±0.23 ^a	2.90±0.408 ^a

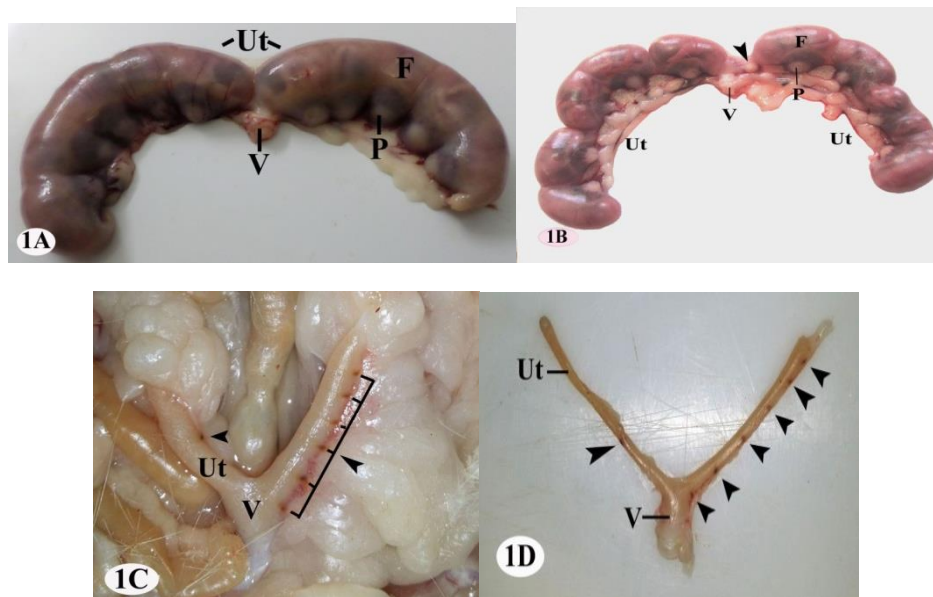


Fig. 1: photographs of the uterus of pregnant rat at the 20th day of gestation.

(A) Control. Showing normal symmetrical distribution of fetuses in the two uterine horns.

(B, C, D) Treated. Illustrating the resorbed embryonic sites (arrow head) F: fetus, P: placenta, Ut: uterus, V: vagina

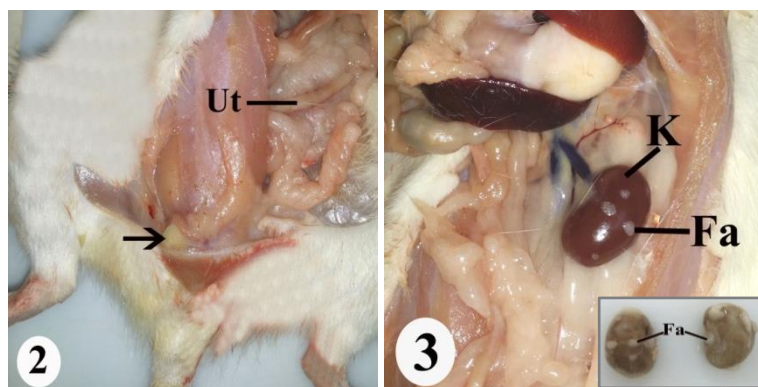


Fig. 2: photographs of the uterus of pregnant rat at the 20th day of gestation showing an abscess in the pelvic region (arrow)

Fig. 3: photographs of the kidney of pregnant rat at the 20th day of gestation showing scattered fat cells on the wall of the kidney. Fa: fats, K: kidney

The impact of yeast tablets on fetuses

The treated fetuses with mums orally ingested with yeast tablets showed some morphological abnormalities. The weights and lengths of fetuses were significantly decreased (Table 1). No mortality cases were registered (Table 2). The morphological examination revealed the appearance of a congenital deformity of the hind limb or what is known club foot and hematoma at the different parts of the body as on the head, back and fore limb (Fig. 4& Table 3).

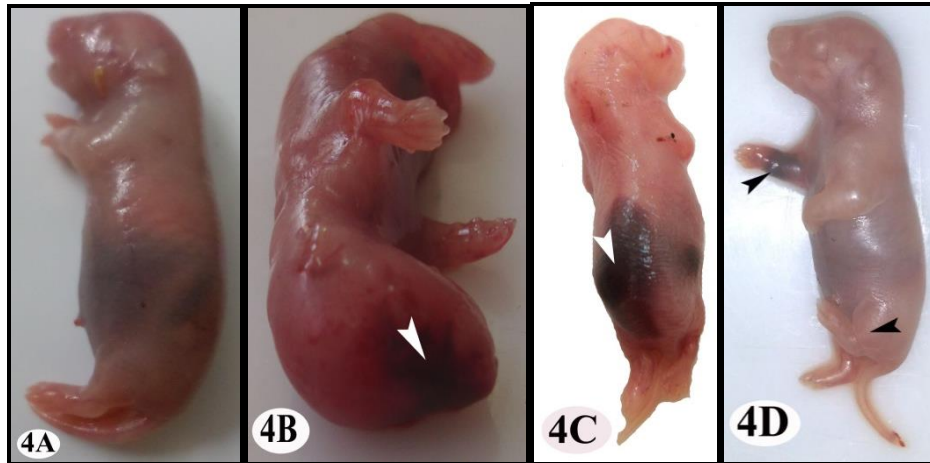


Fig. 4: Photographs of mothers' fetuses at 20th day of gestation. Control (A). Fetus exhibits normal morphology. Treated (B, C, D) demonstrating hematoma in the head, back and fore limb (arrowhead), club foot (arrow)

Table 2: Showing pregnancy outcome of rats treated with yeast tablets.

Group	No. of fetuses	Dead fetus	Resorbed fetus	No. of implantation sites	Post implantation loss
Control	82	0	0	82	0
Treated with 41.1 mg/kg	49	0	14	63	22

Table 3: Elucidating the effect of yeast on fetus morphology at 20th day of gestation.

Group	No. of examined fetuses	Hematoma	For limb anomalies	Hind limb anomalies
Control	82	0	0	0
Treated with 41.1 mg/kg	49	13	0	4

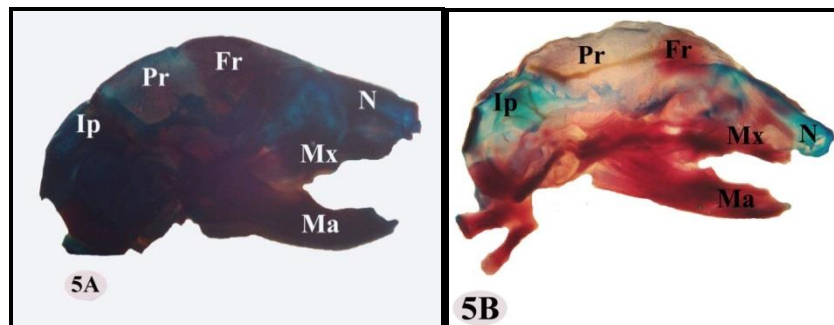


Fig. 5: Photographs of the fetuses' cranial skeleton at 20th of gestation. (The bones were stained with Alcian blue & Alizarin red stain).

(A) The cranial skeleton of control fetus showing complete ossification of the cranial bones.
 (B,C) The cranial skeleton in fetuses of dams treated with yeast tablets showing incomplete ossification in the nasal (N) and interparietal (Ip) bones.

Mx: maxilla, Ma: mandible, Fr: frontal, Pr: parietal.

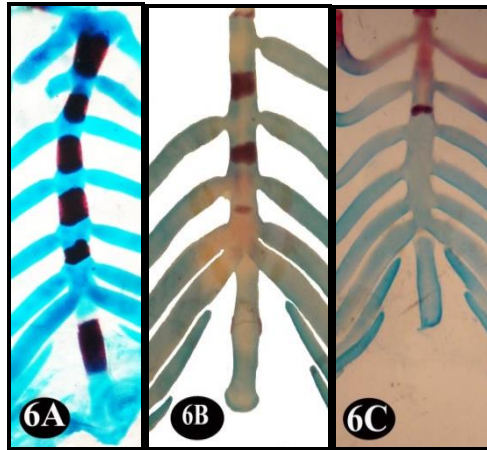


Fig. 6: Photographs of the sternum of fetuses at 20th of gestation. (Alcian blue & Alizarin red stain).
 (A) The sternum of control fetuses showing complete ossification of sternbrae bones.
 (B,C) The sternum of maternally treated fetuses fine ossified and unossified sternbrae bones.

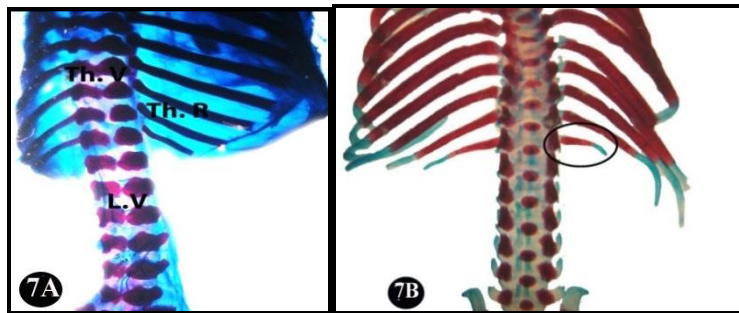


Fig. 7: Photographs of the ribs of fetuses at 20th of gestation (Alcian blue & Alizarin red stain).
 (A) The ribs of control fetuses showing normal shape of ribs.
 (B) The ribs of fetuses maternally treated with yeast tablets showing abnormal shortage in the last thoracic rib.

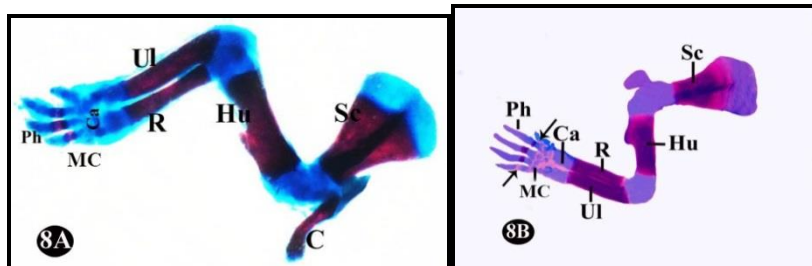


Fig. 8: Photographs of the pectoral girdle and fore limb of fetuses at 20th of gestation. (Alcian blue & Alizarin red stain).
 (A) The pectoral girdle and fore limb of control fetuses exhibiting complete ossification of all bones.
 (B) The pectoral girdle and fore limb of fetuses maternally treated with yeast tablets showing unossified metacarpalia (arrow) of metacarpals (MC). C: clavical, Ca: carpals, Hu: humerus, R: radius, Sc: scapula, Ph: phalanges UI: ulna.

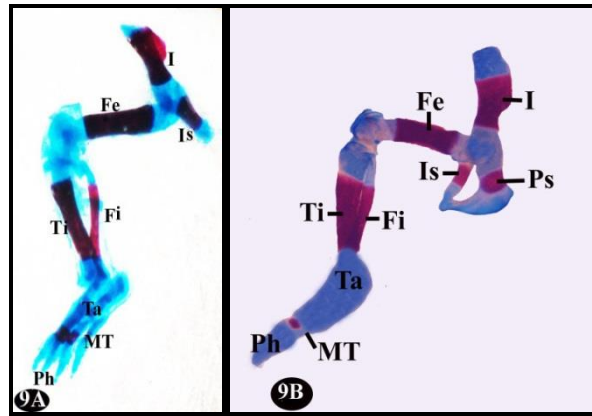


Fig. 9: Photographs of the pelvic girdle and hind limb of fetuses at 20th of gestation. (Alcian blue & Alizarin red stain).
(A) The pelvic girdle and hind limb of control fetuses with normal bones.
(B,C) The pelvic girdle and hind limb of fetuses maternally treated with yeast tablets illustrating incomplete ossification in particular in the metatarsals (MT).
I: ilium, Is: ischium, Ps: pubis, Fe: femur, Fi: fibula, Ti: tibia, Ph: phalanges.

The administration of therapeutic dose of yeast tablets during the gestation period induced some skeletal anomalies in both axial and appendicular skeleton compared to the control group that having skeleton with normal size and shape, all the bones in a well ossified condition stained red. The fetuses of the treated dams showed skeletal anomalies in the sternum, ribs, fore- and hind-limbs. The skeletal abnormalities include delayed ossification of the skull, sternum vertebrae, metacarpals and metatarsals. The anomalies of the ribs appeared in the presence of abnormal shortage of the last thoracic vertebrae.

DISCUSSION

It is a general concept that administration of drugs during pregnancy should be guarded because of its embryo toxicity, but seldom to forewarn from the intake of the probiotics during this period because of its safety and good dietary supplement believing that it is fetal innocuous. The abnormalities or the teratogenicity in the embryonic development depends on the period of organogenesis taking place from the occurrence of the neural plate to formation of the neural tube. This period begins in human on 18th-21st days and continued for 36 days. As well in the rats it starts on 6th days and prolonged for 10 days [18] and reported by [19] and [20]. Oral administration of the yeast tablets during the period of organogenesis displayed a significant increase in the pregnant dams' weight change and accumulation of the fats on their bodies in particular around the kidney and placenta. The marked increase in the body weight and deposition of fats was due to the addition of yeast (*Saccharomyces cerevisiae*) was indicated by [21-23]. Likewise, exposure increased the chance of fetal and skeletal abnormalities. On the contrary, there is a significant decrease in the weight and length of fetuses and higher incidence of resorption and post implantation death. No mortality cases were recorded in this study. The number of live fetuses per dams decreased due the high percentage of the resorbed embryos. No results were reported a teratogenic effect of fetuses due to the treatment of the yeast tablets so, we recommended further studies on this scope because of its utmost importance.

Reduction in the fetal body weight is an indication of growth retardation. [24] recorded that acute interruption of blood flow to the uterine horn led to growth retardation of the fetuses. [25] listed that lessening in the uterine vascularization thence lowered blood flow to the uterine horn and this induces fetal-placental growth retardation. Reduction in the fetal weight accompanied by delayed ossification of the fetal skeleton.

Additional fetal distortions were observed in the hematoma and clubfoot. [26] listed that the congenital clubfoot deformity might be due to one of three causes that are (i) indirect action of yeast tablets, (ii) alteration of maternal physiology, which disturbs the hormonal balance in mother, or (iii) direct effect on the tissue primordial of foot.

Skeletal malformation or dysplasias are a heterogeneous and complex group of conditions affecting both bone growth and development resulting in various anomalies in the shape and size of the skeleton [27].

Skeletal malformations are clinically important as they are associated with severe disability and may cause death [28]. Because of partial ossification of the fetal rodent skeleton, single staining of bone cannot precisely describe normal and abnormal fetal skeletal structures. Although of these restrictions the single stain for bone is universally used in routine teratology tests, as it is simpler and cheaper than double staining methods (29). In spite of these unossified structures become ossified as development resumes, Alizarin Red S does not specifically stain these cartilaginous precursors of bone, and this technique is not useful for specific identification of cartilage [29&30]. Inability to evaluate the cartilaginous parts of the skeleton might lead to failure to recognize important abnormalities in skeletal morphology. The double staining method for fetal skeletons was suggested many years ago by different investigators, with small differences in methodology [19].

The double staining of the maternally treated fetal skeleton exhibit reduced ossification in the skull bones (as nasal, frontal, parietal and interparietal bones), sternum vertebrae, metacarpals, metatarsals and shortage in the last thoracic ribs. This reduced ossification of various bones may be due to modify calcium metabolism or lowered calcium and magnesium ion levels as well as altered calcitonin level in the growing fetus, thereby causing retardation in bone development.

Summing up the results observed in this study it may be declared that taking the yeast tablets during the pregnancy period causes some anomalies to the embryos even if not serious it is aberration from the normal. Therefore, we advise to avoid the intake of these tablets during pregnancy without doctor consulting and also, we recommended further studies in this study.

REFERENCES

- [1] Sanchez NCB, Young TR, Carroll JA, Corley JR, Rathmann RJ, Johnson B J. Yeast cell wall supplementation alters the metabolic responses of crossbred heifers to an endotoxin challenge. *Innate Immunol* 2014; 20:104–112.
- [2] Van der Peet-Schwering CMC, Jansman AJM, Smidt H, Yoon I. Effects of yeast culture on performance, gut integrity, and blood cell composition of weanling pigs. *J Anim Sci* 2007; 85:3099–3109.
- [3] Tripathi MK, Karim SA. Effect of yeast cultures supplementation on live weight change, rumen fermentation, ciliate protozoa population, microbial hydrolytic enzymes status and slaughtering performance of growing lamb. *Livest Sci* 2011; 135:17-25.
- [4] Dawson KA. The application of yeast and yeast derivatives in the poultry industry. *Proc Aust Poult Sci Sym* 2001; 13:100-105.
- [5] Beauchemin KA, Kreuzer M, O'Mara F, McAllister TA. Nutritional Management for enteric methane abatement: a review. *Australian J Expt Agric* 2008; 48:21-27.
- [6] Broadway PR, Carroll JA, Sanchez NCB. Live Yeast and Yeast Cell Wall Supplements Enhance Immune Function and Performance in Food-Producing Livestock: A Review. *Microorganisms* 2015; 3: 417-427.
- [7] Delcenserie V, Martel D, Lamoureux M, Amiot J, Boutin Y, Roy D. Immunomodulatory effects of probiotics in the intestinal tract. *Curr Issues Mol Biol* 2008; 10: 37-54.
- [8] Schlee M, Harder J, Kotten B, Stange EF, Wehkamp J and Fellermann K. Probiotic lactobacilli and VSL#3 induce enterocyte β -defensin 2. *Clin Exp Immunol* 2008; 151: 528- 535.
- [9] Lipiński K, Chrostowski G, Matusevičius P, Skórko-Sajko H, Stasiewicz M, Purwin C, Pysera B. The effect of diets supplemented with *Saccharomyces cerevisiae* boulardii probiotic yeast on the reproductive performance of pregnant and lactating sows. *veterinarijairzooteknika* 2012; 59(81).
- [10] Fang Z, Zhao M, Zhen H, Chen L, Shi P and Huang Z. Genotoxicity of Tri- and Hexavalent Chromium Compounds *In Vivo* and Their Modes of Action on DNA Damage *In Vitro*. *PLoS ONE* 2014; 9(8).
- [11] Althuis MD, Jordan NE, Ludington EA, Wittes JT. Glucose and insulin responses to dietary chromium supplements: a meta-analysis. *Am J Clin Nutr* 2002; 76:148–155.
- [12] Cefalu WT, Hu FB. Role of chromium in human health and in diabetes. *Diabetes Care* 2004; 27:2741–2751.
- [13] Langard S. One hundred years of chromium and cancer: a review of epidemiological evidence and selected case reports. *Am J Ind Med* 1990; 17:189–215.
- [14] Levina A, Lay P. Chemical properties and toxicity of chromium (III) nutritional supplements. *Chem. Res. Toxicol* 2008; 21:563-571.

- [15] Eastmond DA, MacGregor JT, Slesinski RS. Trivalent Chromium: Assessing the Genotoxic Risk of an Essential Trace Element and Widely used Human and Animal Nutritional Supplement. *Crit. Rev. Tox* 2008; 38 (3), 173-190.
- [16] Nasrin SS, Naser S, Marziyeh, Mohammad NH. Teratogenic effects of sulfur mustard on mice fetuses. *Iranian J. Basic Med. Sci* 2012; 15(3): 859-853.
- [17] Redogan D, Kadioglu D, Peker T. Visualization of the fetal skeletal system by double staining with Alizarin red and Alcian blue. Gazi University, faculty of medicine, Departments of Histology-Embryology and Anatomy, Ankara, Turkey. *Gazi medicinal journal* 1995; 6: 55-58.
- [18] Vickers M, Brackley K. Drugs in pregnancy. *Curr. Obstet. Gynaecol* 2002; 12: 131-137.
- [19] Soysal H, Unur E, Düzler A, Karaca Ö, Ekinci N. Effects of intraperitoneal administration of the phenytoin on the skeletal system of rat fetus. *Seizure* 2011; 20: 187-193.
- [20] El Ghareeb AA, Hamdi H, Taha EF and Abdelrahman HA. Evaluation of Teratogenic potentials of Bronchodilator drug on offsprings of Albino rats. *International Journal of Scientific & Engineering research* 2015; 6 (3): 534-542.
- [21] Lyngs B. Vaegtuduiklingofoderbrug hos solu-ogblaracuehualpe. *Dansk Pelsdyraavl* 1990; 6: 296-297.
- [22] Zduńczyk Z. Physiological effect of low digestible oligosaccharides in diets for animals and humans. *Polish Journal of Food and Nutrition Science* 2004; 13(54): 115-130.
- [23] Przysiecki P, Filistowicz A, Filistowicz A, Fuchs B, Nawrocki Z, Řehout V, Rząsa A, Nowicki S. Effect of addition of yeast (*Saccharomyces cerevisiae*) and herb preparation to feed on selected physiological indicators, growth rate and pelt quality of growing arctic foxes. *Animal Science Papers and Reports* 2010; 28(3): 261-270.
- [24] New DA, Coppola PT. Development of a placental blood circulation in rat embryos in vitro. *Journal of Embryology and Experimental Morphology* 1977; 37: 227-235.
- [25] Garris, DR. Intrauterine growth of the guinea pig fetal-placental unit throughout pregnancy: regulation by uteroplacental blood flow. *Teratology* 1984; 29 (1): 99-93.
- [26] Sharma S, Mathur U, Saini MR, Sharma MK, Kumar M, Kumar A. Fetal malformation in Swiss albino mice on exposure to lead during gestation period. *Bulletin of Environmental Science* 2001; 19 (200): 81-84.
- [27] Khundan SK. Common Fetal Abberations and their teratologic significance – A review. *Fundamental and Applied Toxicology* 1981; 1: 13-18.
- [28] Cassart M. Suspected Fetal Skeletal Malformations Or Bone Diseases: How To Explore, *Journal of Pediatric Radiology* 2010; 40: 1046-1051.
- [29] Menegola E, Broccia ML, Di Renzo F, Giavini E. Comparative study of sodium valproate-induced skeletal malformations using single or double staining methods. *Reprod Toxicol* 2002; 16(6): 815-23.
- [30] Burdan F, Rozylo-Kalinowska I, Rozylo TK, Chahoud I. A new, rapid radiological procedure for routine teratological use in bone ossification assessment: a supplement for staining methods. *Teratology* 2002; 66: 315-325.